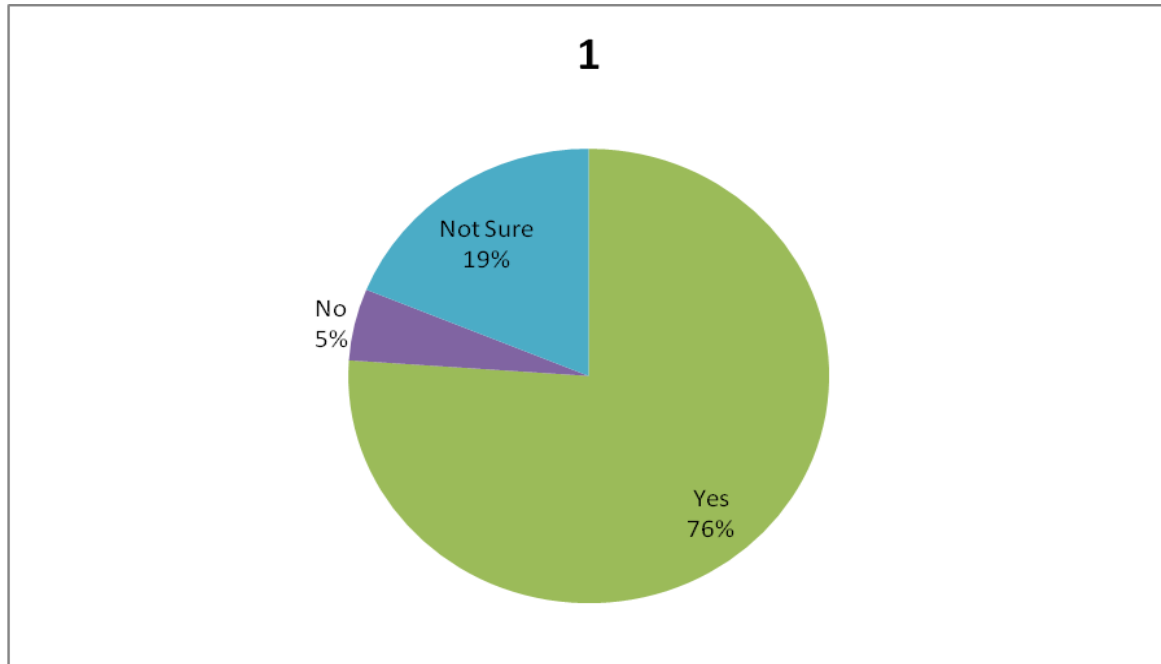
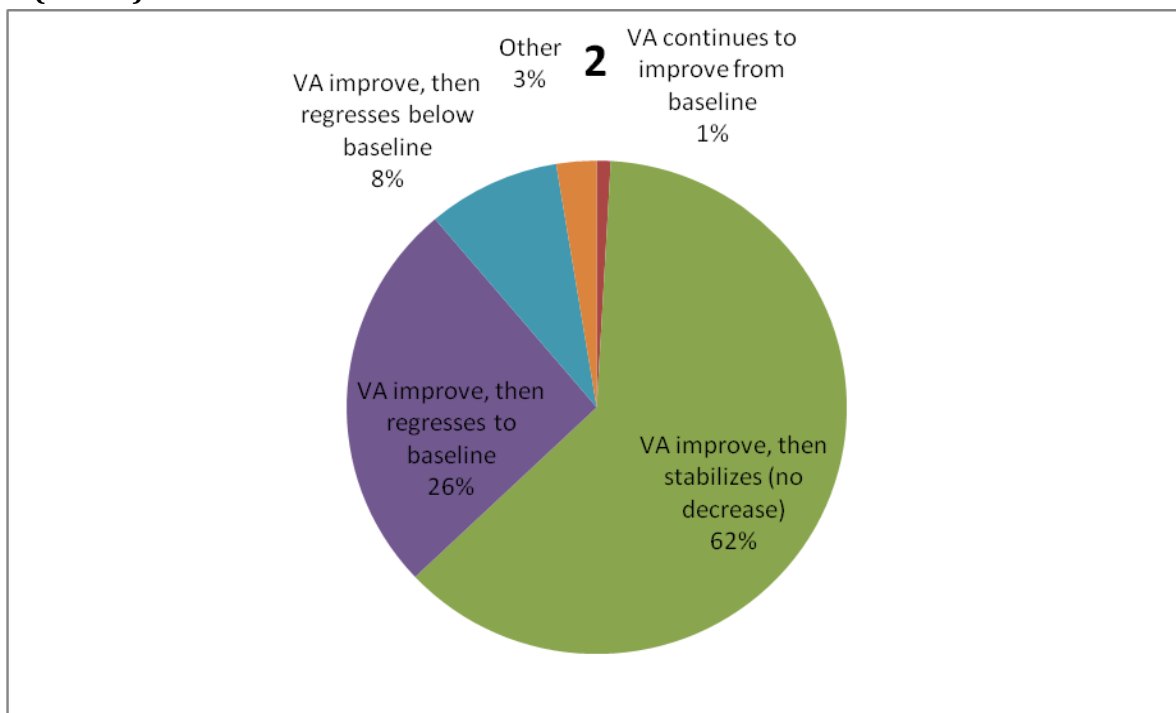


**RESULTADO SURVEY ASRS 2016**  
**RESPUESTAS DE LOS MIEMBROS DE LA**  
**SOCIEDAD ARGENTINA DE RETINA Y VÍTREO**

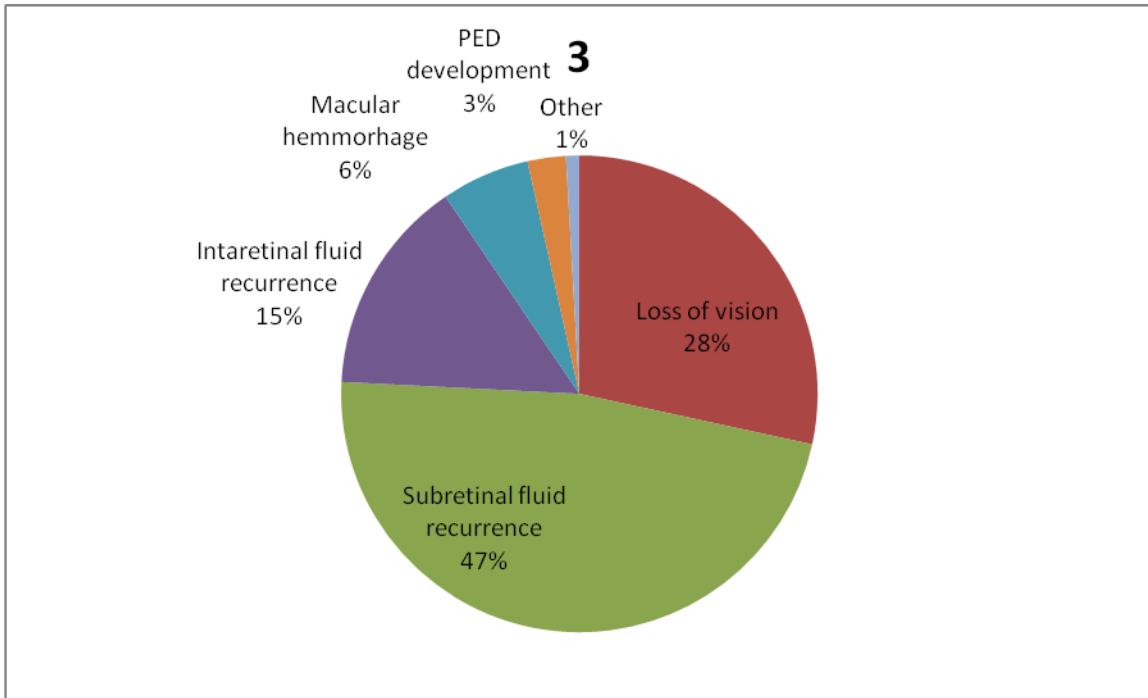
**1. Do you believe switching anti-VEGF agents makes an impact on the visual acuity (VA) of wet-AMD patients? (n=117)**



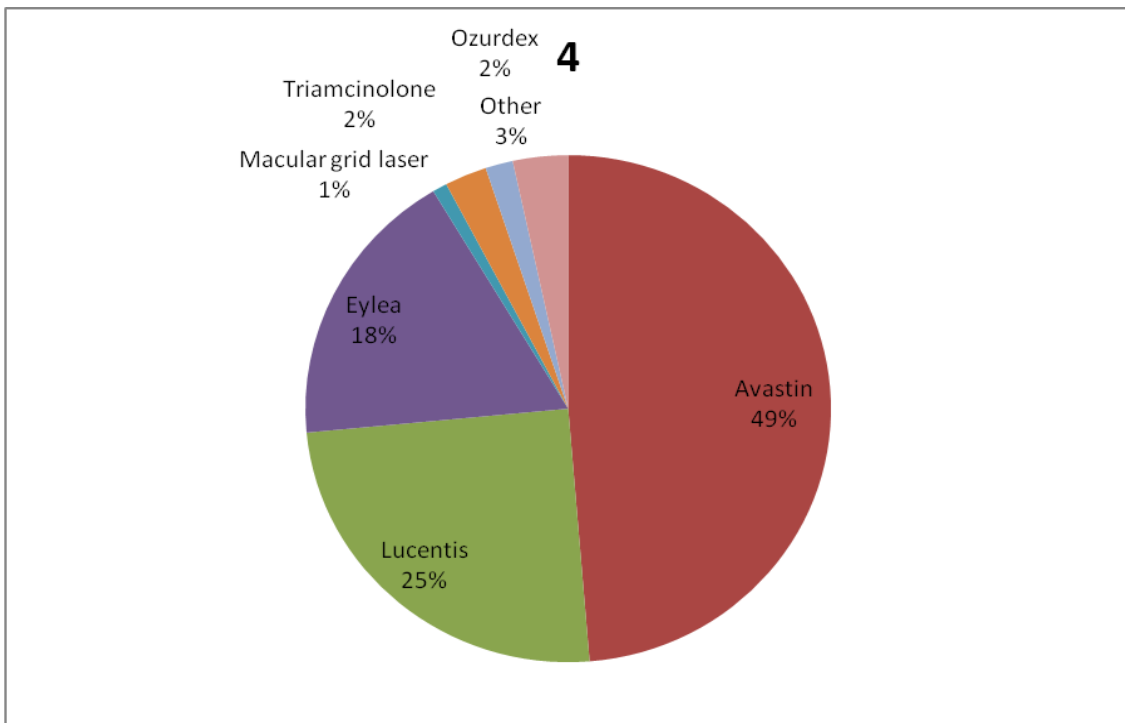
**2. What is your experience during chronic treatment for wet AMD (2 or more years) with anti-VEGF agents? (n=116)**



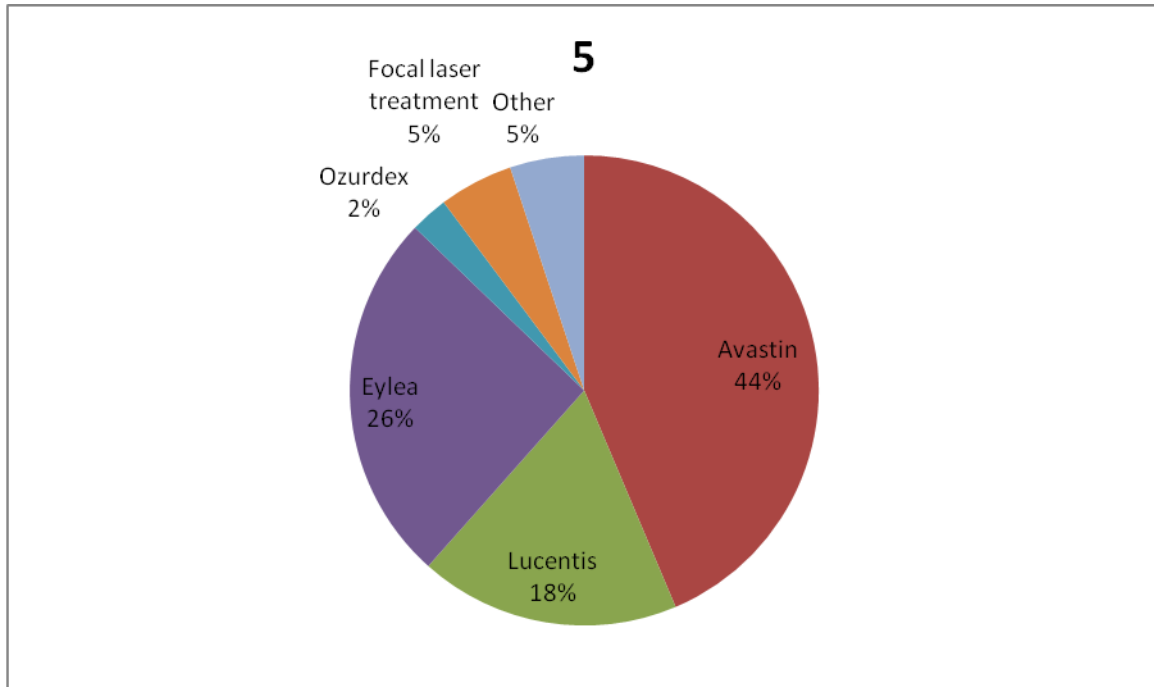
**3. In your opinion, what is the most important factor indicating recurrent disease activity in wet AMD during the maintenance phase? (n=116)**



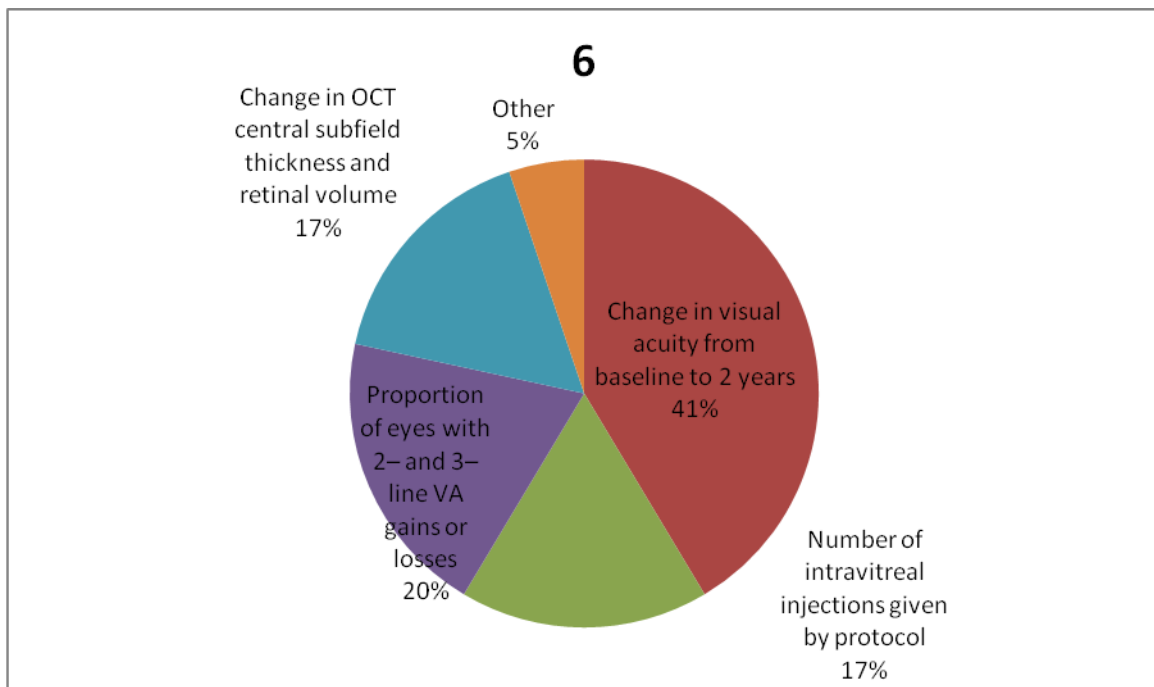
**4. A 72-year-old patient presents with a perfused branch retinal vein occlusion (BRVO) with macular edema and VA of 20/60 (decreased vision). What is your initial treatment recommendation? (n=117)**



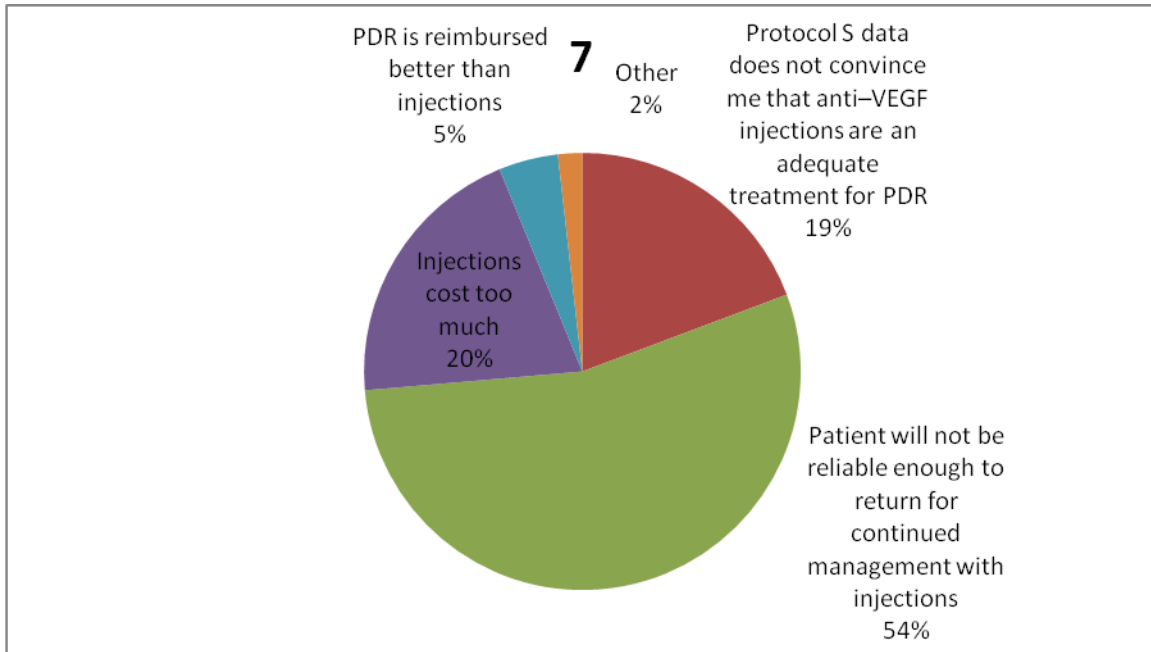
**5. What is your first choice of treatment for patients with decreased vision due to diabetic macular edema (DME)? (n=117)**



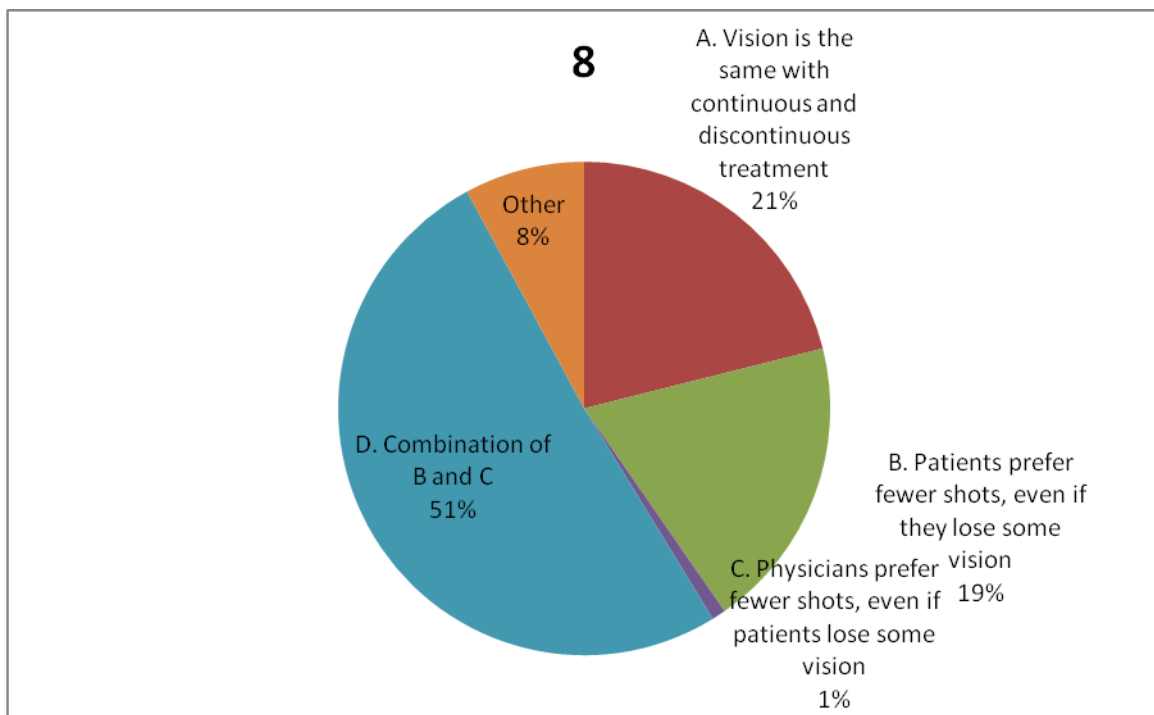
**6. Which Diabetic Retinopathy Clinical Research Network (DRCR.net) Protocol T 2-year efficacy outcome will most affect your anti-VEGF choice for treating DME? (n=116)**



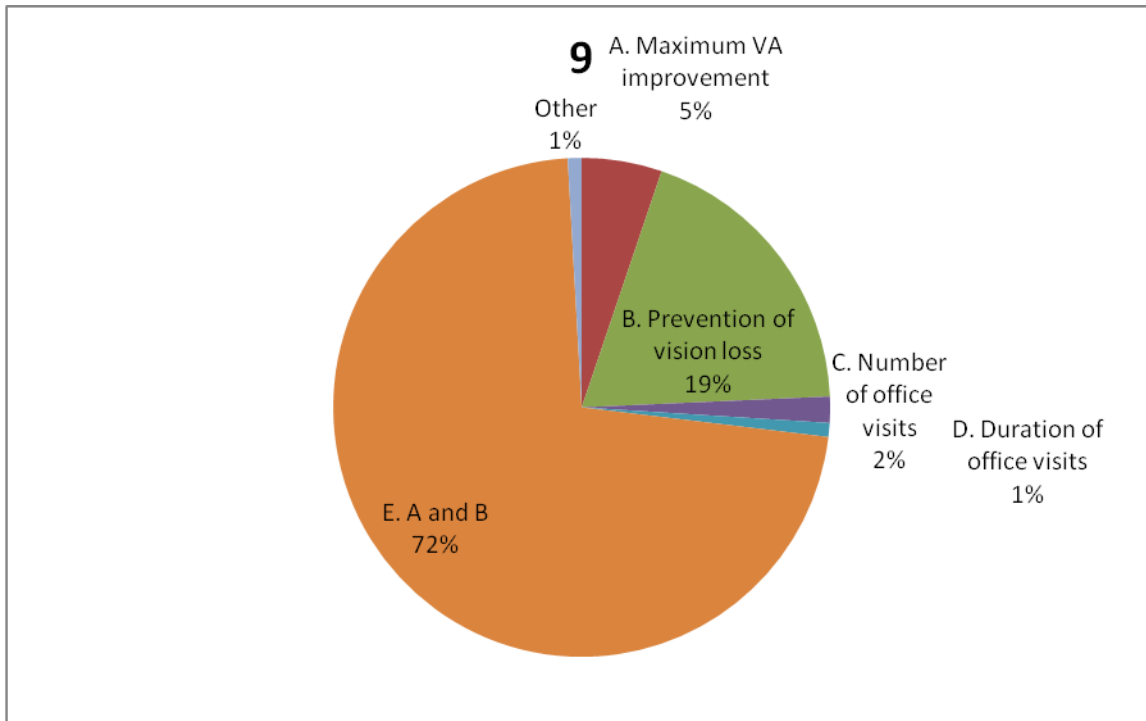
**7. When considering treatment for proliferative diabetic retinopathy (PDR), published results from DRCR.net Protocol S suggest Lucentis injections have similar vision outcomes at 2 years to panretinal photocoagulation (PRP) with less loss of peripheral vision. Which factor would MOST lead you to choose PRP to treat a patient? (n=114)**



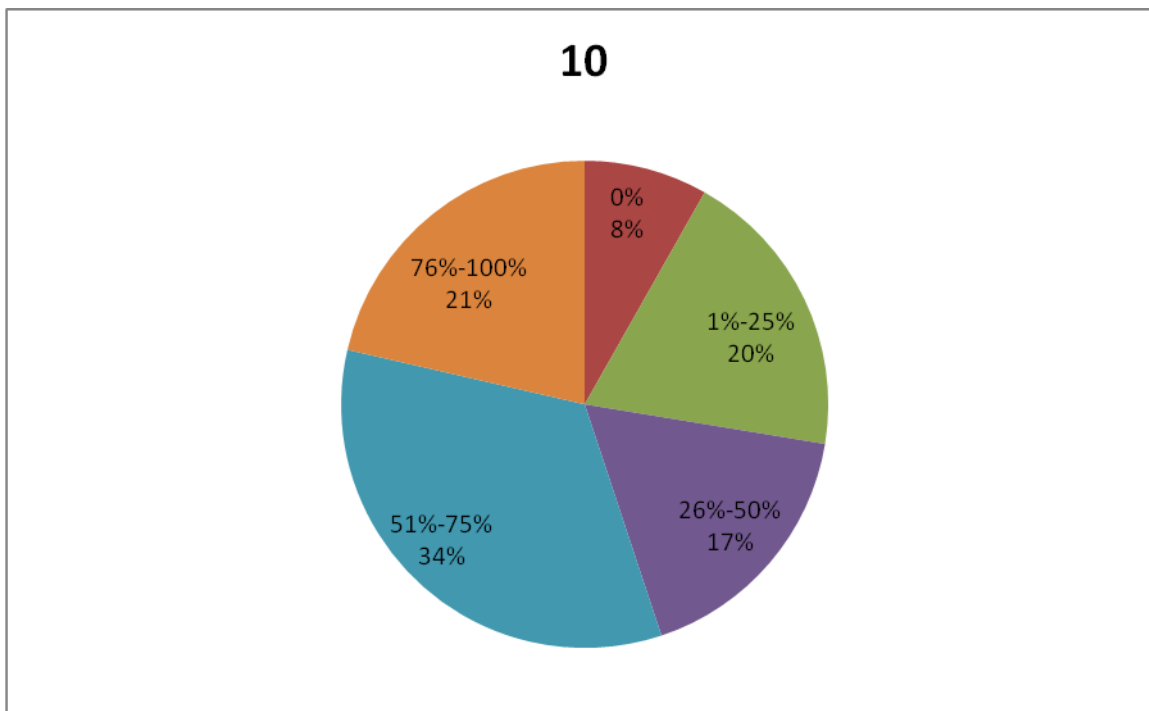
**8. Why do you believe discontinuous anti-VEGF treatment in wet AMD is the most common treatment regimen used by retina specialists? (n=114)**



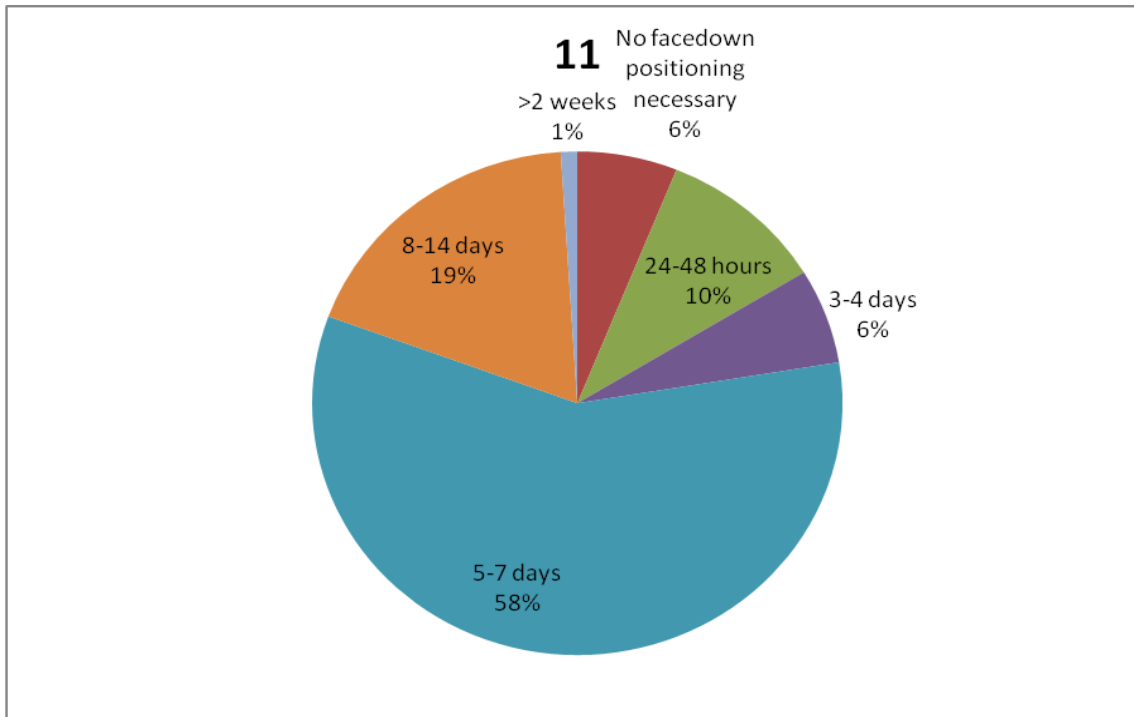
**9. What do you think is most important for elderly patients with loss of vision? (n=115)**



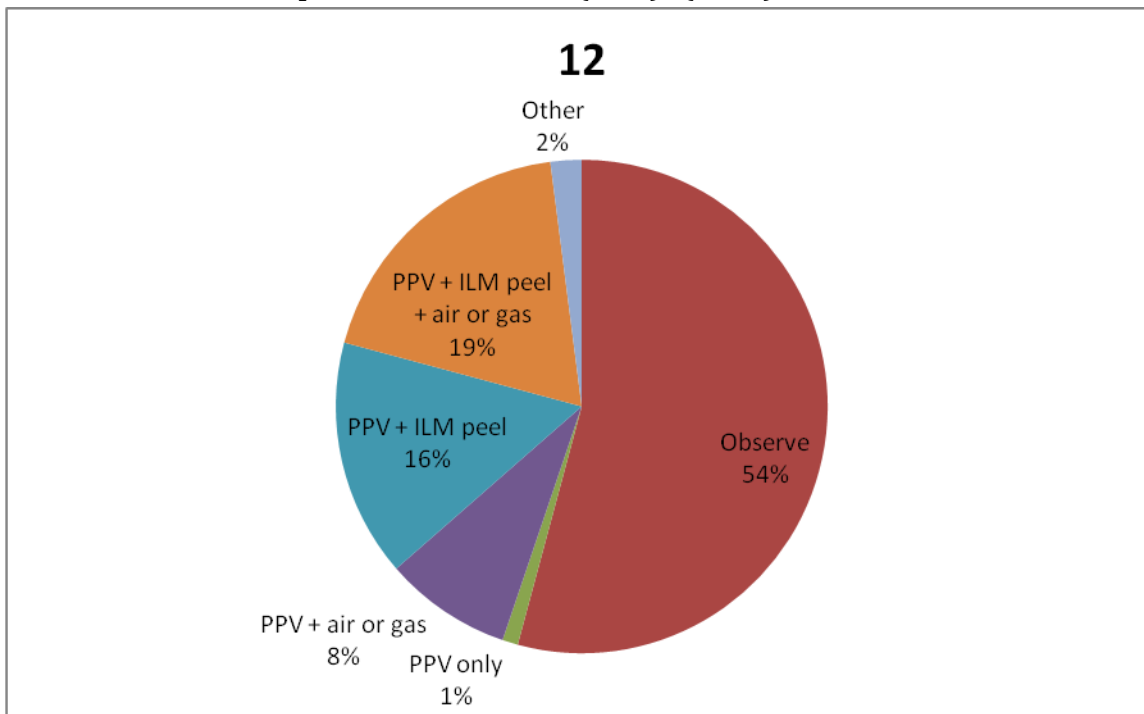
**10. What percentage of the time do you use perfluorocarbon liquid in vitrectomy for routine primary rhegmatogenous retinal detachment without proliferative vitreoretinopathy (PVR)? (n=98)**



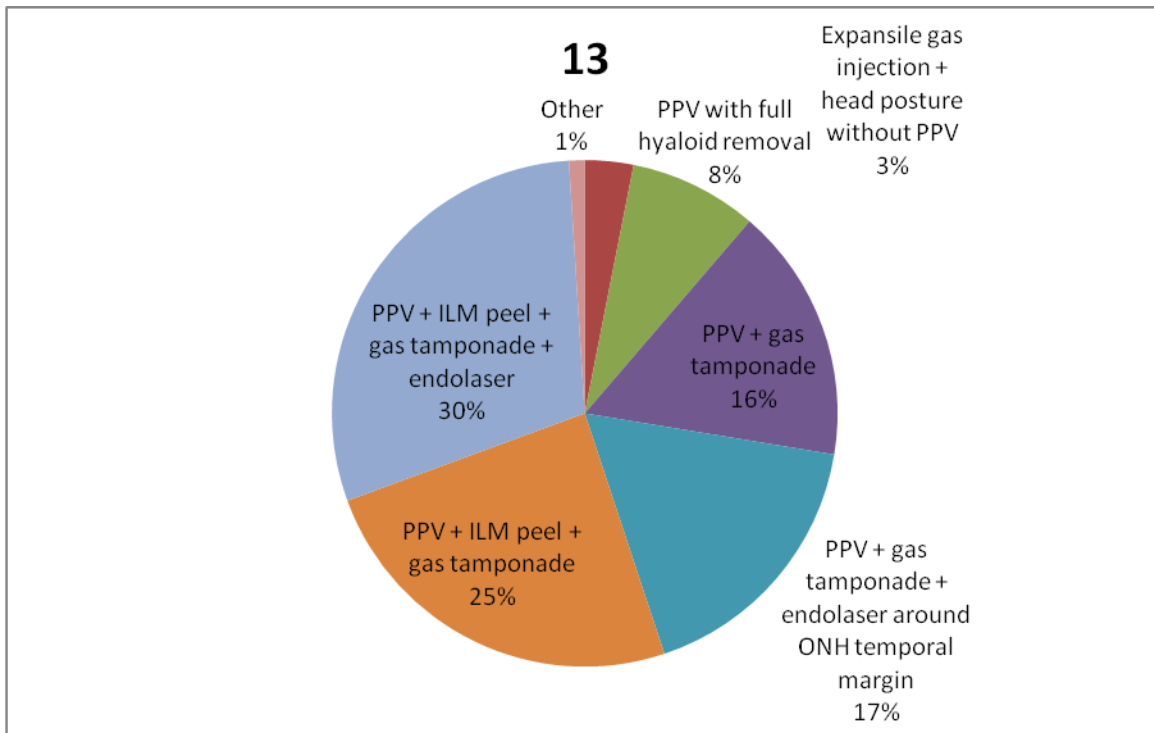
**11. How long do you recommend face-down positioning after macular hole repair? (n=98)**



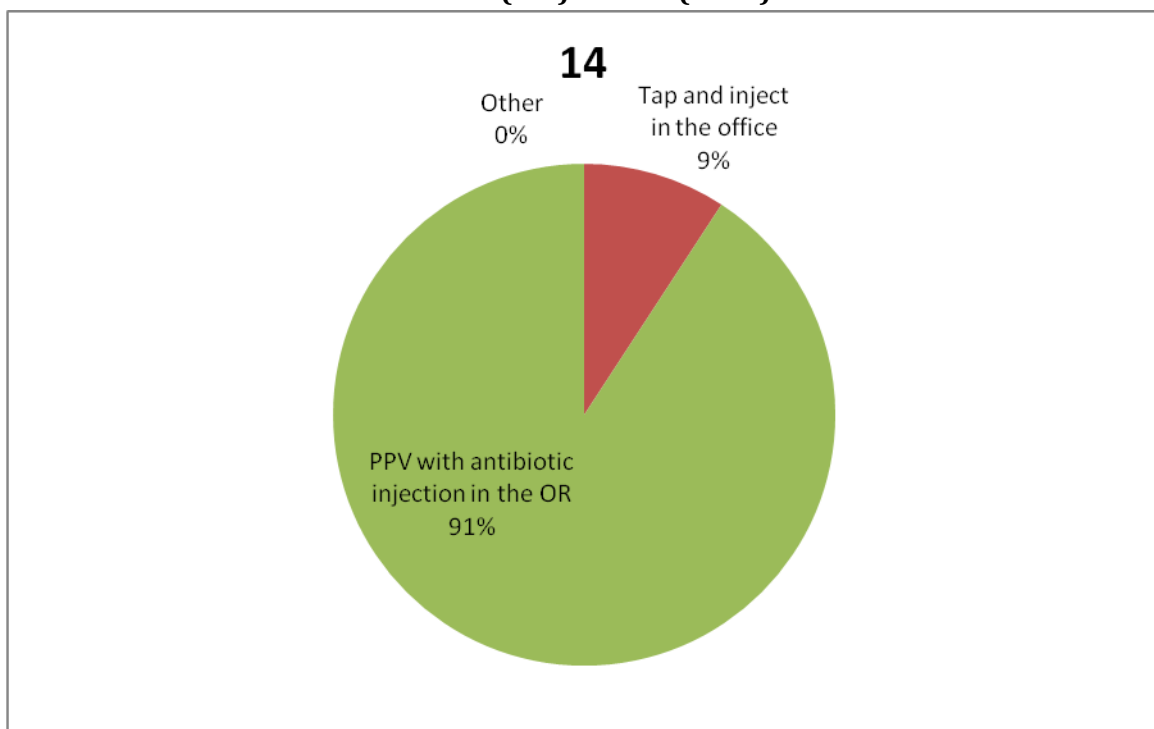
**12. Which of the following best describes your current management of a symptomatic patient with spectral-domain OCT (SD-OCT) findings of inner lamellar macular hole WITHOUT vitreomacular traction and no evidence of epiretinal membrane (ERM)? (n=98)**



**13. Assuming you decide to treat, which surgical approach best describes your preferred option for managing optic disc pit-associated maculopathy? (n=98)**



**14. How would you manage a patient with endophthalmitis post intravitreal injection with hand-motion (HM) vision? (n=98)**



15. How would you manage a patient with endophthalmitis post vitrectomy surgery with HM vision? (n=98)

